

Otitis: Precautions and Techniques During Deep Ear Cleaning

Kim Knowles, D.V.M., Diplomate ACVIM (Neurology)

Donald C. Levesque, D.V.M., Diplomate ACVIM (Neurology)

Ear flushing is extremely important in the management of both chronic and acute otitis but flushing too vigorously or too often with potentially ototoxic agents can do more harm than good. Hazards of deep ear cleaning include contact irritation of the external ear canal, inadvertent rupture of the tympanum, introduction of pathogens into the middle ear, and serious vestibular and/or auditory disturbances. Owners need to be advised (preferably in writing) of potential risks associated with this procedure, even when carried out with the utmost of care.

Pathophysiology of Neural Dysfunction

In some cases of acute deafness/vestibular dysfunction following ear flushing, the signs result from pathogenic bacteria in the external ear canal or middle ear cavity that have gained entrance to the inner ear as a result of the procedure. In others, liberated bacterial exotoxins (toxic or serous labyrinthitis) may cause the clinical signs as opposed to direct bacterial invasion. Signs may be due to a perilymphatic fistula (abnormal communication between the perilymphatic space and middle ear) caused by a cotton-tipped applicator or other object rupturing the oval and/or window membrane or fracturing the stapes (Fig 1). Perilymphatic fistulas can also result from barotrauma due to pressure changes associated with ear flushing.

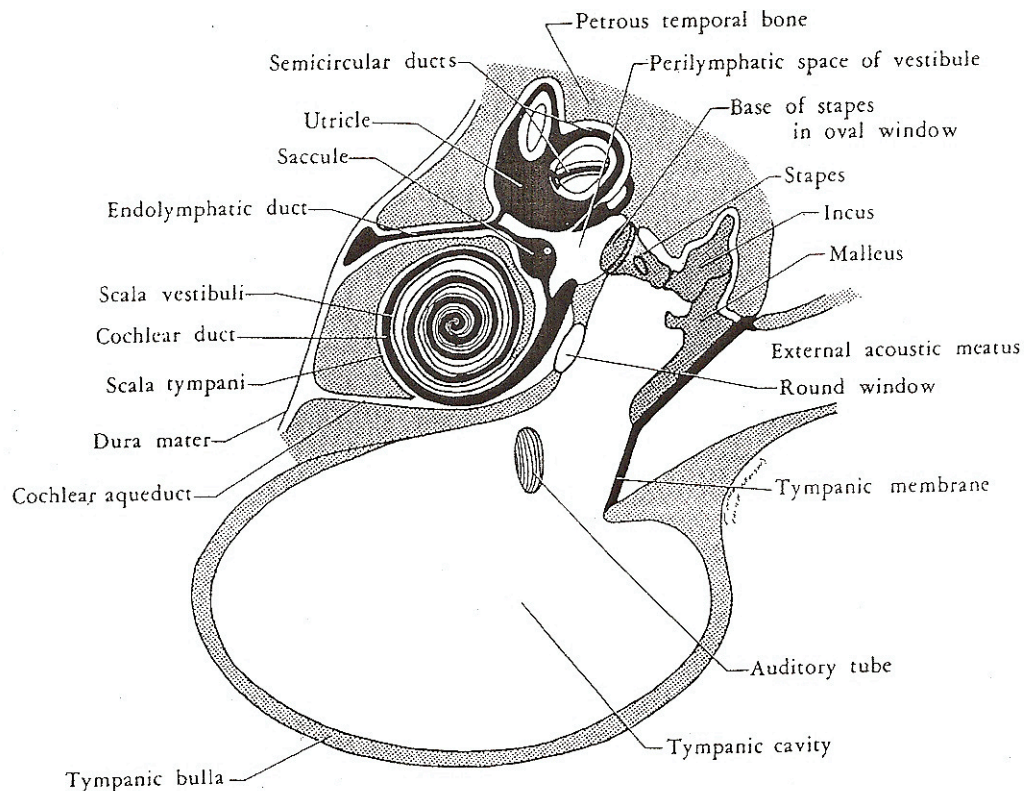


Fig 1. Diagram of the middle ear (tympanic cavity) and inner ear (labyrinth) of dog. (Jenkins T.W., Functional Mammalian Neuroanatomy, Second Edition, 1978).

Diagnostics

In patients with concurrent neurological signs (ipsilateral Horner's syndrome, facial palsy, peripheral vestibular signs or auditory dysfunction) radiography or advanced CT or MRI is recommended prior to ear cleaning (Fig 2 & 3). If imaging studies are only performed after deep ear cleaning, it is difficult to determine if fluid present in the middle ear was iatrogenically introduced or part of the disease process. Radiographic evaluation of the bullae includes ventrodorsal, lateral, oblique and open mouth views. Unfortunately, normal radiographs do not rule out middle ear disease. CT and MRI are more sensitive than plain radiography in detecting changes in the bullae and surrounding soft tissues.

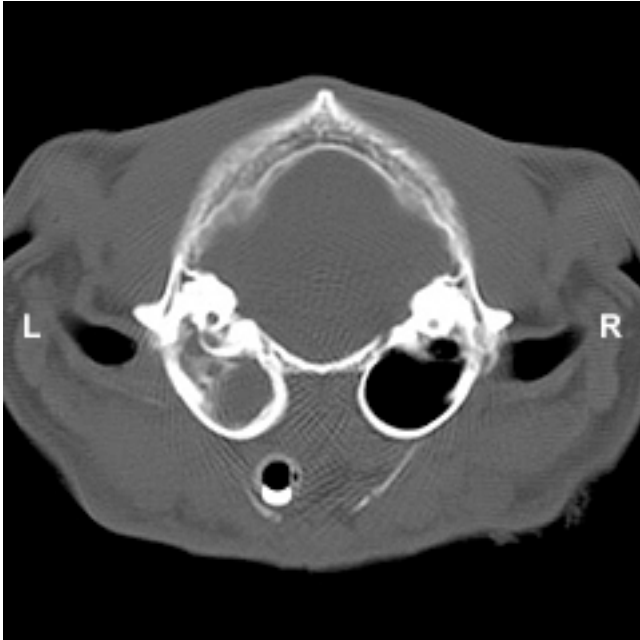

Fig 2. Axial CT Image (Abnormal Left Bulla)

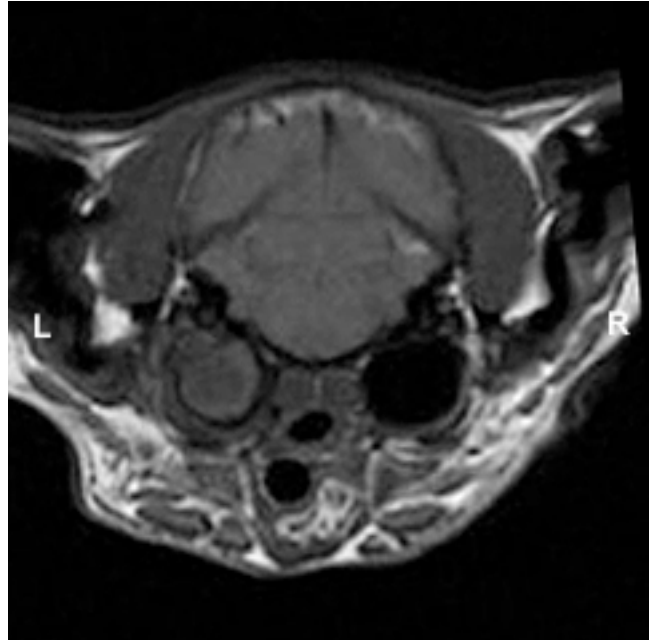


Fig 3. Axial T1 MR Image (Abnormal Left Bulla)

General Guidelines for Ear Flushing

- Deep ear cleaning should be done under deep sedation or general anesthesia and should only be performed by a veterinarian. Intubation is advised since stimulation of the distal ear canal can induce laryngospasm or vomiting.
- Cytology and culture of exudate should be obtained prior to ear flushing.
- Small pieces of wax within the vertical portion of the ear canal can easily be removed with a dull buck ear curette. Alligator forceps may be used to remove larger particulate material and hair. Avoid the temptation to use forceps to remove material that appears closely and tightly adherent to the tympanum. Try to soften with ceruminolytics and use gentle suction to remove such material (see suggested technique, below).
- Visually confirm that the tympanum is intact before instilling any potentially ototoxic medication.
- If the tympanum cannot be visualized, the best advice is to assume it is ruptured or severely diseased.
- The type of flushing solution used depends on the degree of inflammation, character of the aural discharge and whether the tympanum is intact. In cases of perforation or when the integrity of the eardrum is unknown, irrigation with warm saline is advised. Gently lavage and massage the ear canal with either warm saline or a dilute solution of a warm ceruminolytic to loosen and remove wax and debris. For deep and thorough cleaning, a small, 5-6 mm diameter, soft, silicon or surgical

rubber tubing is attached to a 6 -12 ml syringe. The tubing should be soft so as not to mechanically puncture the tympanum and small enough in diameter to allow venting of pressure and excess solution while flushing. A low pressure, vacuum suction apparatus attached to the above small diameter, soft tubing is used to atraumatically remove debris.

- Avoid excessive pressure when flushing the external ear canal, and pay particular attention to ensure that the syringe or syringe tubing does not fill the entire canal (there must be room around the tube for venting pressure). Failure to take this precaution will likely result in rupturing the tympanum and possibly the oval and round window membranes. The latter is the most likely cause of injury to the tympanum and middle ear structures and will allow entry of potential pathogens and ototoxic medications into the inner ear.
- If the tympanum is ruptured and ceruminolytics have been used, gently but copiously lavage the ear canal and middle ear cavity with a warm saline solution. Treat with systemic medications and do not prescribe topical preparations.
- Know when to stop! At times, it is impossible to completely clean the ears during the first treatment and the procedure may need to be repeated at a later date following a course of topical or systemic treatment.

Treatment

The goals of treatment are to remove infected material or debris from the external ear to provide an avenue for ventilation and drainage, to address any predisposing causes (swimming, atopy), and to minimize recurrence, complications and sequelae. Most cases of otitis externa require daily topical medication. Commercially available eardrops contain various combinations of antibacterial, antifungal, antiparasitidal and antiinflammatory agents. One should be alert to the potential hypersensitivity and ototoxic properties of neomycin. In the presence of an open middle ear, avoid topical preparations if possible and never use lipid-based preparations. Systemic antibiotics are warranted if otitis externa is chronic or complicated by otitis media/interna. Selection is based on cytology, culture and sensitivity results. Commonly used antibiotics are amoxicillin with clavulanic acid, first-generation cephalosporins and enrofloxacin. Long-term (3-6 weeks) therapy is usually required in cases of otitis media/interna.

Patient Monitoring

Follow-up otoscopic examinations are the most important factors in the successful management of otitis. Recheck patients every 1-2 weeks until adequate response is seen.

Client Communication

Because the vestibular and auditory systems are very sensitive and delicate, the important topic of client communication must be stressed. Although these systems are well protected within the skull, seemingly minor disturbances and injuries can cause dramatic and debilitating signs. Owners need to be aware of the risks of ear disease and its treatment. It is not unreasonable to have a written waiver form signed by the owner of every patient whose ears are to be treated. The following might serve as a potential model:

“Your pet has evidence of ear canal inflammation. Although the thought of general anesthesia for ear cleaning may at first appear unreasonable, it is not. In order to safely and gently clean your pet's ears without discomfort, general anesthesia is strongly recommended. Pre-existing infections often cause damage and weakening of the eardrum and even careful, gentle cleaning of ear canals can result in eardrum perforation. Eardrum perforation may allow medications or infections to enter the inner ear

structures resulting in balance dysfunction that can persist for several weeks. Deafness can also be caused by infections, drugs, or injury of the inner ear; it may be permanent depending on the cause. The risk of eardrum perforation and hearing and balance disturbances can be greatly minimized if ear cleaning is done under general anesthesia."

I have read and understand the above statement and hereby grant permission allowing my pet to be anesthetized for ear treatment.

Client Signature

Date

Prognosis of Neural Dysfunction

In most cases, the hearing loss and/or vestibular signs associated with otitis interna are mild and show partial to complete recovery if properly treated. A 3-6 week course of systemic antibiotics is recommended. However, the occurrence of neural dysfunction following deep ear cleaning can be unpredictable and the signs (particularly reduced auditory function in cats) can be permanent. These risks are minimized if appropriate precautions have been taken.